

Pancreatic cancer Staging report - 01/03/2017



Anonymous Male (M)

ID: 20170301_Pancreas_01

Tumor Assessment

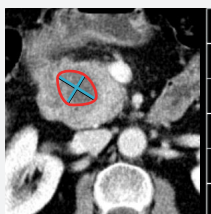Category Borderline resectable

Malignant lesion

PA01 Pancreas

Area: 319 mm²
SA: 18.7 mm
LA: 24.6 mm

CT: SE 3; IN 23; TP -139
New



Visible local tumor:	Present
Density:	Hypodense
Invasion of adjacent structures:	Present

General Assessment

Pancreatic Duct and Biliary Tree

Upstream dilatation of pancreatic duct:	Present
---	---------

Localisation of pancreatic duct narrowing leading to upstream dilatation:	Head
---	------

Maximum diameter of pancreatic duct:	5 mm
--------------------------------------	------

Abnormal widening of common bile duct:	Present
--	---------

Maximum diameter of common bile duct:	5 mm
---------------------------------------	------

Local Tumor Burden

Invasion of small bowel:	Present
--------------------------	---------

Infiltration of locoregional lymph node metastases:	Present
---	---------

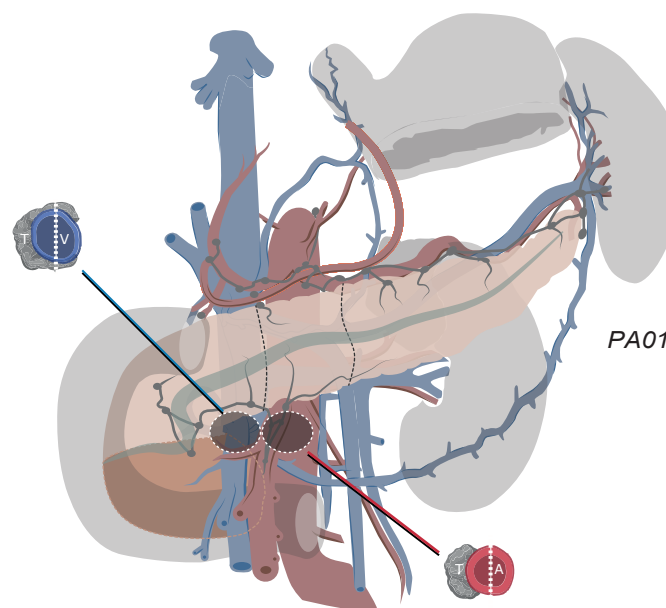
Arterial Evaluation

Degree of solid soft-tissue contact with celiac axis:	No tumor contact
---	------------------

Variant anatomy of celiac axis (Michelis Classification):	Michelis 1 (Norm. arterial variant)
---	--

Disease overview

The following diagram is an abstract representation of the disease. It does not depict real patient anatomy.



Lesion PA01:  Head of pancreas involved

General Assessment (continued)

Arterial Evaluation

Degree of solid soft-tissue contact with superior mesenteric artery:	Abutment (contact $\leq 180^\circ$)
--	---

Venous Evaluation

Degree of solid soft-tissue contact with main portal vein:	No tumor contact
--	------------------

Degree of solid soft-tissue contact with superior mesenteric vein:	C or D - Tumor contact with deformity
--	---

Degree of solid soft-tissue contact with inferior vena cava:	No tumor contact
--	------------------

Distant metastasis

Ascites:	Present
----------	---------

Assessment

Resectability:	Borderline
----------------	------------